

# Gluteal fasciocutaneous rotational flap and its role in the management of complex sacrococcygeal pilonidal sinus disease: a case-series study

Mohamed F. Abdelhalim, Mohamed A. Elbegawy

Department of General Surgery, Benha Faculty of Medicine, Benha University, Benha, Egypt

Correspondence to Mohamed Farid Abdelhalim, MD, Benha, Qalubia, Postal Code 13511. Mob: 01005004354; e-mail: Faridsurgeon82@gmail.com

**Received:** 4 February 2021

**Revised:** 19 February 2021

**Accepted:** 7 March 2021

**Published:** 12 October 2021

**The Egyptian Journal of Surgery** 2021, 40:594–599

## Background

Complex sacrococcygeal pilonidal disease is an aggressive disease that requires a wide excision of the whole natal cleft and all involved tissues. This extensive excision results in a defect that is not pliable for primary closure. Reconstruction of the defect by an ideal flap is a practical option.

## Objective

This study aimed at assessing the feasibility and the efficacy of the gluteal fasciocutaneous rotational flap in the management of complex sacrococcygeal pilonidal sinus disease.

## Patients and methods

During the period from April 2018 to March 2020, 40 patients with complex sacrococcygeal pilonidal sinus disease presented to the General Surgery Department, Benha University Hospital, for management of this complex disease. All the patients underwent complete excision of the disease and reconstruction of the defect by a gluteal fasciocutaneous rotational flap.

## Results

The study group included 40 patients. The mean age $\pm$ SD was 27.03 $\pm$ 7.26. Five (12.5%) patients had recurrent disease. The mean operative time was 55.0  $\pm$ 8.16 min. All patients were discharged within 24 h postoperatively. The mean time to return to normal daily activities was 2.55 $\pm$ 0.68 days, whereas the mean time to return to work was 2.91 $\pm$ 0.87 weeks, and the mean follow-up was 14.95 $\pm$ 3.2 months (range, 10.0–18.0 months). One (2.5%) patient had a recurrence in the second year of the follow-up.

## Conclusion

Gluteal fasciocutaneous rotational flap is a feasible, simple, and reliable method for reconstruction of a wide defect after excision of a complex sacrococcygeal pilonidal sinus disease.

## Keywords:

complex sacrococcygeal pilonidal sinus disease, gluteal rotation flap, pilonidal sinus, reconstruction

Egyptian J Surgery 40:594–599

© 2021 The Egyptian Journal of Surgery

1110-1121

## Introduction

Sacrococcygeal pilonidal sinus disease is a common chronic inflammatory disease of the natal cleft [1]. It is predominant in young adults with coarse body hair and particularly in males with a ratio of about 4 : 1 [2]. It is an acquired disorder caused by broken hairs that penetrate the deep natal cleft and initiate foreign body reaction and inflammation [3]. Pilonidal disease presents a wide spectrum of clinical manifestations, ranging from asymptomatic conditions such as cysts and sinuses to multiple abscesses [4]. In the chronic phase, there are fistulous openings or pits with continuous or intermittent serous or purulent discharges [5]. There are heterogeneous therapeutic modalities for the management of sacrococcygeal pilonidal sinus disease ranging from simple incision to complex flaps with controversy over the best method to treat this disorder [6]. Occasionally, some patients with recalcitrant disease

present by recurrent abscesses and multiple, splitting sinus tracts and pits. This condition is called complex pilonidal disease, which requires extensive wide excision and more complex reconstructive procedures [7]. These procedures include Z-plasty closure, Limberg transposition flap, V-to-Y advancement flaps, gluteus maximus myocutaneous flap, and fasciocutaneous rotational flap [8].

## Objective

This case-series study was designed to assess the feasibility and the efficacy of the gluteal

This is an open access journal, and articles are distributed under the terms of the Creative Commons Attribution-NonCommercial-ShareAlike 4.0 License, which allows others to remix, tweak, and build upon the work non-commercially, as long as appropriate credit is given and the new creations are licensed under the identical terms.

fasciocutaneous rotational flap in the management of complex sacrococcygeal pilonidal sinus disease.

### Patients and methods

During the period from April 2018 to March 2020, 40 patients with complex sacrococcygeal pilonidal sinuses presented to the General Surgery Department, Benha University Hospital, for management of this complex disease. Ethical approval for this study was obtained from ethics committee of Benha University. All the patients underwent complete excision of the disease and reconstruction of the defect by a gluteal fasciocutaneous rotation flap. The approach and its adverse events were explained to each patient. Written consent was taken from each patient. The variables assessed were age, sex, operative time, duration of hospital stay, time to restore normal daily activities and return to work, and postoperative complications including recurrence rates at 6–18-month follow-up.

Study design: prospective case-series study.

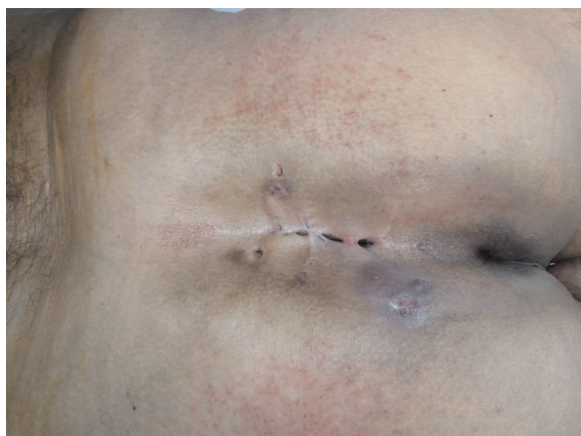Inclusion criteria: age more than or equal to 17 years. Primary or recurrent complex sacrococcygeal pilonidal sinuses with multiple sinus tracts and pits or cysts.

Exclusion criteria: asymptomatic pilonidal sinus; a disease with associated skin disorders as psoriasis in the intergluteal region.

### Operative procedure

All patients were anesthetized by spinal anesthesia. A prophylactic antibiotic dose ceftriaxone 1g was administered to all patients. Skin preparation was achieved using 10% povidone–iodine. The patients were placed in the prone position (Figs 1 and 2).

Figure 1



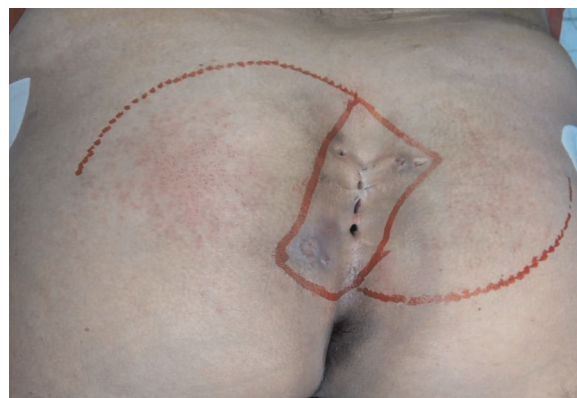Complex sacrococcygeal pilonidal sinuses and cysts.

Methylene blue was injected into the sinuses. Surgical excision of the complex sacrococcygeal pilonidal sinuses and cysts, involving complete natal cleft excision, reaching presacral fascia, was undertaken (Figs 3 and 4). The gluteal fasciocutaneous rotation flap was tailored by a curvilinear incision and released off the gluteus maximus muscle (Figs 5 and 6). The wound was closed on a vacuum drain that was removed when the drainage was 50 ml or less per day (Fig. 7). The patients were advised to avoid sitting and tension on the flap. The skin clips were removed on the 12th postoperative day.

### Follow-up

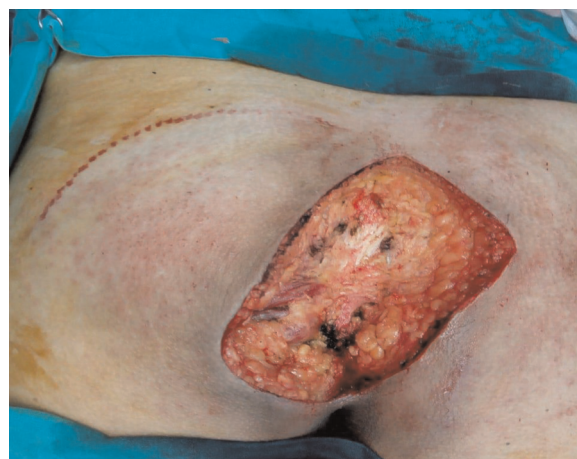The patients were followed up the first week, the second week, 1 month, and 6 months after the operation. In the successive times, the patients were examined every 6 months to assess the recurrence (Figs 8 and 9).

Figure 2



Excision plan of the natal cleft and design of the rotational flap.

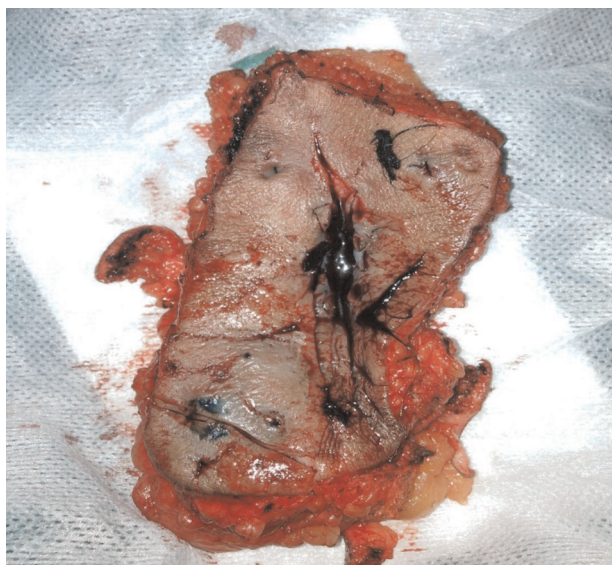
Figure 3



Excised sacrococcygeal pilonidal sinus.

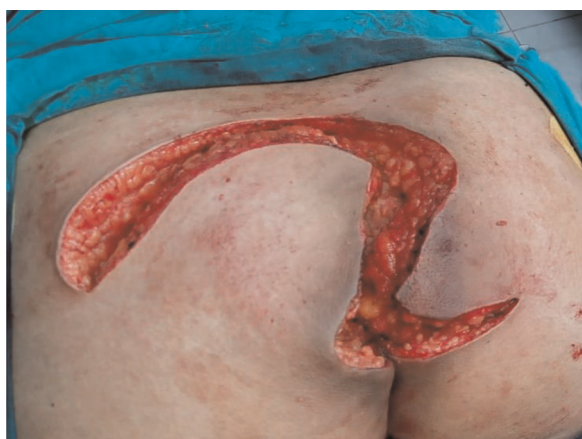

Figure 4



The specimen excised.

Figure 5



Curvilinear incision for the gluteal fasciocutaneous rotational flap.

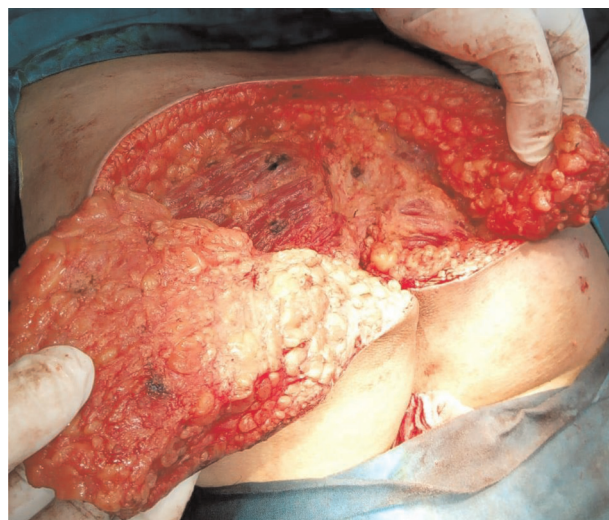### Statistical analyses

Software (SPSS, version 26.0 for Windows, SPSS Inc., Chicago, Illinois, USA) was used for analysis of the data. Quantitative data were summarized using mean and SD, while qualitative data by using frequency and percentage.

### Results

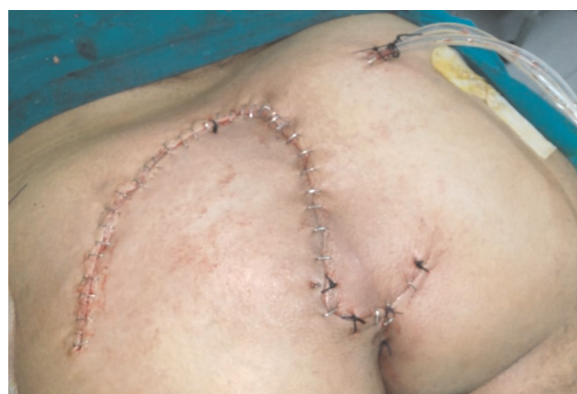A total of 40 patients with complex sacrococcygeal pilonidal sinus disease were selected for management by gluteal fasciocutaneous rotational flap between April 2018 and March 2020, in the General Surgery Department, Benha University Hospital. Of these patients, 36 (90%) were males and four (10%) were females. Mean age±SD was 27.03±7.26 (range, 17.0–45.0). Five (12.5%) patients had recurrent disease (Table 1).

Figure 6



The flap was released off the gluteus maximus muscle.

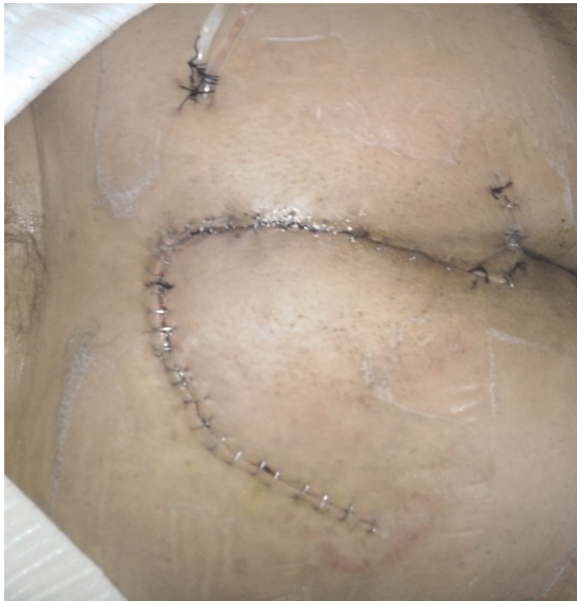Figure 7



Closure of the defect with the flap.

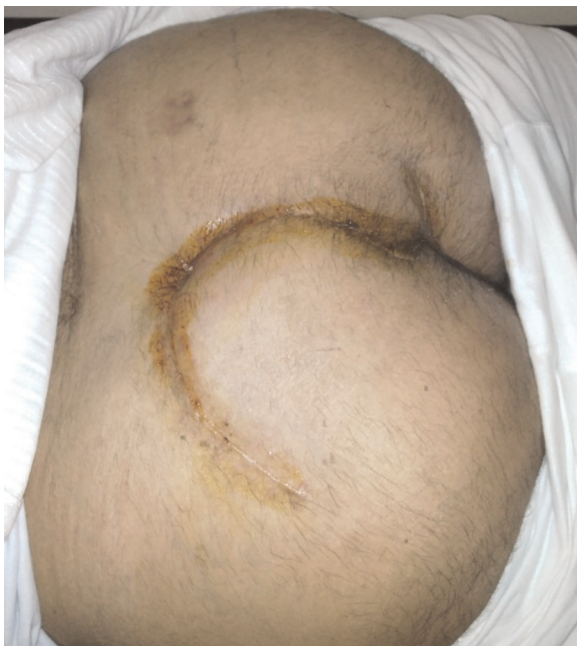The mean operative time was 55.0±8.16 min (range, 45.0–70.0 min). All patients were discharged within 24 h postoperatively. The mean visual analog scale for the postoperative pain on the first day was 6.38±1.15 (range, 5.0–8.0). The mean time to return to normal daily activities was 2.55±0.68 days (range, 2.0–4.0 days), whereas the mean time to return to work was 2.91±0.87 weeks. The mean time for toilet sitting was 11.53±1.55 days (range, 10–14), whereas the mean time for drain removal was 15.2±3.77 days (10.0–20.0 days) and the mean follow-up was 14.95 ±3.2 months (range, 10.0–18.0 months). Major complications were not detected; however, there was seroma in five (12.5%) patients. Surgical-site infection developed in three (7.5%) patients. There were three (7.5) cases of partial flap necrosis, one (2.5) case of flap dehiscence, one (2.5) case of hematoma, and three (7.5) cases of loss of sensation of skin over the flap. The

Figure 8



Flap appearance 1 week after the operation.

Figure 9



Flap appearance 3 weeks after the operation.

overall postoperative complications were managed conservatively. One (2.5%) patient had a recurrence in the second year of the follow-up.

### Discussion

Pilonidal disease is a common problematic benign disease and a surgical challenge [7]. Several surgical procedures have been described for its management, but failure and recurrence rates are prevalent and variant [9]. Among these procedures, minimally

Table 1 Distribution of the studied group (N=40)

	n (%)
Sex	
Male	36 (90.0)
Female	4 (10.0)
Age (years)	
Mean±SD (range)	27.03±7.26 (17.0–45.0)
Primary or recurrent	
Primary	35 (87.5)
Recurrent	5 (12.5)
Operative time (min)	
Mean±SD (range)	55.0±8.16 (45.0–70.0)
Hospital stay (h)	
12	12 (30.0)
24	28 (70.0)
VAS score	
Mean±SD (range)	6.38±1.15 (5.0–8.0)
Return to daily activity (day)	
Mean±SD (range)	2.55±0.68 (2.0–4.0)
Time to toilet sitting (day)	
Mean±SD (range)	11.53±1.55 (10–14)
Time for drain removal (day)	
Mean±SD (range)	15.2±3.77 (10.0–20.0)
Return to work (week)	
Mean±SD (range)	2.91±0.87 (2.0–4.0)
Complications	
Partial flap necrosis	3 (7.5)
Seroma	5 (12.5)
Surgical-site infection	3 (7.5)
Flap dehiscence	1 (2.5)
Hematoma	1 (2.5)
Recurrence	1 (2.5)
Loss of skin sensation	3 (7.5)
Follow-up period (months)	
Mean±SD (range)	14.95±3.2 (10.0–18.0)

invasive techniques, such as fibrin glue, crystallized phenol, laser, and endoscopic interventions, are favored for small pilonidal sinus disease [10]. Excisional procedures include excision and lay open technique, and excision, then primary closure, or utilizing various flap techniques (Limberg/Dufourmentel flap, Karydakias flap, V-Y-advancement flap, and Z-flap) [9]. Complex sacrococcygeal pilonidal disease is an aggressive disease that requires a more extensive surgical approach through a wide excision of the whole natal cleft and all involved tissues [7]. This extensive excision results in a defect that is not pliable for primary closure [11]. Reconstruction of the defect by an ideal flap is a practical option [7]. In this study, the feasibility and efficacy of gluteal fasciocutaneous rotational flap in the management of complex pilonidal sinus and its outcomes were assessed by recruiting 40 patients with complex sacrococcygeal pilonidal sinus disease. A rotational flap is a simple and effective method to close a surgical defect not amenable to primary closure



by using the reservoir of tissue laxity and redirecting vectors of tension [12]. Through the rotational flaps, the recipient site obtains the same skin color, texture, and thickness from the donor site [13]. Deep natal cleft is an important factor in the pathogenesis of pilonidal sinus disease [14]. Gluteal fasciocutaneous rotational flap can eliminate this factor by flattening the natal cleft as well as it provides tensionless wound closure. In our study, the mean operative time was  $55.0 \pm 8.16$  min. All patients were discharged within 24 h postoperatively. The mean time to resume normal daily activities was  $2.55 \pm 0.68$  days, whereas the mean time to return to work was  $2.91 \pm 0.87$  weeks. The mean time for drain removal was  $15.2 \pm 3.77$  days and the mean follow-up was  $14.95 \pm 3.2$  months with one case of recurrent disease. The follow-up period was not longer enough to assess the actual recurrence rate. However, these results are comparable to other flap methods used for the treatment of pilonidal sinus disease, such as Limberg flap, Karydakias flap, and V-Y flap. Ates *et al* [15] reported in their prospective randomized study that the mean operative time for the Karydakias group was  $42.32 \pm 8.64$  min and that for the Limberg group was  $50.14 \pm 6.96$  min. The mean duration values of the hospital stay for the Karydakias group and the Limberg group were  $3.40 \pm 0.94$  and  $3.8 \pm 1.19$  days, respectively. Recurrence rates were 3% in the Karydakias group, and 6.9% in the Limberg group. Koca *et al.* [16] reported in their study of the assessment of the V-Y-flap technique in complicated and recurrent pilonidal sinus disease, that the mean duration of operation was  $61.02 \pm 12.30$  min for unilateral V-Y plasty. Drains were removed at  $5.59 \pm 1.91$  days. The mean duration of hospital stay was  $5.98 \pm 2.21$  days and the time to return to work was 21 days. Closure of a large defect after excision of a complex pilonidal sinus by Limberg flap has many drawbacks as the presence of some degree of tension at the suture lines, as well as the presence of cosmetically unacceptable multiple horizontal and oblique scars extending across the buttocks, particularly in the case of bilateral Limberg flaps. These drawbacks can be circumvented by the gluteal fasciocutaneous rotational flap [17]. Gluteus maximus myocutaneous flap and its modifications are another method of management of complex pilonidal sinus disease [8]. However, the major drawbacks of gluteus maximus myocutaneous flap are the sacrifice of a deep-functioning muscle, its bulky nature, limited shifting capacity, and the significant morbidities if wound complications take place [3,18]. In our study, the major complications were not detected; however, there was one (2.5) case of hematoma and five (12.5%) patients developed seroma owing to large dissection.

The seroma was observed 1 week after the removal of the drain. Seroma resolved spontaneously in four cases, while one case required repeated aspiration. Surgical-site infections developed in three (7.5%) patients and were treated with proper antibiotics. There was one (2.5) case of flap dehiscence, and three (7.5) cases of partial flap necrosis, which developed at the tip of the flap owing to the presence of some sort of tension. This tension was avoided in subsequent cases by the proper release of the flap, especially at the point of pivotal restraint that is positioned at the incision end. Gluteus maximus fascia was included into the flap that allowed stronger subcutaneous tissue closure and less tension on the skin, as well as reduced potential wound dehiscence. Finally, the gluteal fasciocutaneous rotational flap allows surgeons to perform extensive excision of complex pilonidal disease and the excision of the whole natal cleft without fear of the reconstruction of a resultant wide defect. It is a technically simple, well-vascularized, tensionless, safe method to close a wide defect without the restriction of a patient's movement or deforming the gluteal shape.

---

## Conclusion

Gluteal fasciocutaneous rotational flap is a feasible, simple, and reliable method for reconstruction of a wide defect after extensive excision of a complex sacrococcygeal pilonidal sinus disease.

## Financial support and sponsorship

Nil.

## Conflicts of interest

There are no conflicts of interest.

---

## References

- Milone M, Velotti N, Manigrasso M, Anoldo P, Milone F, De Palma G. Long-term follow-up for pilonidal sinus surgery: a review of literature with meta-analysis. *Surgeon* 2018; 16:315–320.
- Harris C, Sibbald RG, Mufti A, Somayaji R. Pilonidal sinus disease: 10 steps to optimize care. *Adv Skin Wound Care* 2016; 29:469–478.
- Khanna A, Rombeau JL. Pilonidal disease. *Clin Colon Rectal Surg* 2011; 24:46–53.
- Mendes CRS, Ferreira LSM, Salim L. Brazilian and argentinean multicentric study in the surgical minimally invasive treatment of pilonidal cyst. *Arq Bras Cir Dig* 2019; 32:e1447.
- Mahdy T. Surgical treatment of the pilonidal disease: primary closure or flap reconstruction after excision. *Dis Colon Rectum* 2008; 51:1816–1822.
- Neşar G, Kayaalp C, Seven C. Elliptical rotation flap for pilonidal sinus. *Am J Surg* 2004; 187:300–303.
- Bendewald FP, Cima RR. Pilonidal disease. *Clin Colon Rectal Surg* 2007; 20:86–95.
- Rosen W, Davidson JS. Gluteus maximus musculocutaneous flap for the treatment of recalcitrant pilonidal disease. *Ann Plast Surg*. 1996; 37:293–297.
- Stauffer VK, Luedi MM, Kauf P, Schmid M, Diekmann M, Wieferrich K, *et al.* Common surgical procedures in pilonidal sinus disease: a meta-analysis, merged data analysis, and comprehensive study on recurrence. *Sci Rep* 2018; 8:3058.

- 10 Iesalnieks I, Ommer A. The management of pilonidal sinus. *Dtsch Arztebl Int* 2019; 116:12–21.
- 11 Al Maksoud AM, Ahmed I. Rotation flap to cover a large defect on the dorsum of the hand. *J Surg Case Rep* 2015; 2015:rjv139.
- 12 LoPiccolo MC. Rotation flaps-principles and locations. *Dermatol Surg* 2015; 41 (Suppl 10):S247–S254.
- 13 Tschoi M, Hoy FA, Granick MS. Skin flaps. *Clin Plastic Surg* 2005; 32: p261–p273.
- 14 Gavriilidis P, Bota E. Limberg flap versus Karydakis flap for treating pilonidal sinus disease: a systematic review and meta-analysis. *Can J Surg* 2019; 62:131–138.
- 15 Ates M, Dirican A, Sarac M, Aslan A, Colak C. Short and long-term results of the Karydakis flap versus the Limberg flap for treating pilonidal sinus disease: a prospective randomized study. *Am J Surg* 2011; 202:568–573.
- 16 Koca YS, Yıldız I, Ugur M, Barut I. The V-Y flap technique in complicated and recurrent pilonidal sinus disease. *Ann Ital Chir* 2018; 89:66–69.
- 17 Abdelnaby M, Emile SH, El-Said M, AbdelMawla A, Elgendy H, Sakr A, Shalaby M. Rotational gluteal flap versus modified Limberg flap in treatment of sacrococcygeal pilonidal disease. *J Surg Res* 2018; 223:174–182.
- 18 Mahapure KS, Rajput DU. Partially de-epithelised gluteus maximus myofascio-cutaneous advancement flap cover: a newer reconstructive option for sacral defects. *J Aesthet Reconstr Surg* 2018; 4:8.